

# Clinical diagnosis of recurrent caries

IVAR A. MJÖR, B.D.S., M.S.D., M.S., Dr.Odont.

**T**he term “recurrent caries” denotes caries of the tooth at the margin of restorations. The phenomenon has been known since the early days of restorative dentistry,<sup>1</sup> and it was the basis for the extension-for-prevention concept of G.V. Black’s well-established principles of cavity preparation. Since tooth brushing was the only recognized way to prevent caries at that

**Repair and refurbishing of restorations save tooth structure and increase the life span of the restoration.**

time, an obvious solution to prevent recurrent caries was to place the cavosurface margin in a location where the toothbrush might have had access to the plaque. Present-day knowledge calls for approaches other than removal of intact dental tissues to minimize the risk of developing recurrent caries.

Recurrent caries occurs after a restoration has been functional for some time. The term typically is used in North America. Because this type of carious lesion develops after the initial caries has been removed and replaced by a restorative material, the term “secondary caries” is used more commonly than “recurrent caries” in European languages, including English, for caries that has developed adjacent to margins of restorations.

In this article, I review available information related to recurrent caries, including its relative frequency as a reason for the replacement of different types of restorations, the location of the lesions, the bacteriology of the lesions, the criteria for the clinical diagnosis of recurrent caries and treatment of the lesions. In this context, it is important to differentiate recurrent caries from primary caries and remaining caries. Primary caries starts and progresses on an intact, previously unrestored tooth

**Background.** The clinical diagnosis of recurrent caries is the most common reason for replacement of all types of restorations in general dental practice. Marked variations in the diagnosis of the lesions have been reported. The prevention of recurrent lesions by the use of fluoride-releasing restorative materials has not been successful.

**Types of Studies Reviewed.** The author focused on practice-based studies in the literature. These studies are not scientifically rigorous, but they reflect “real-life” dental practice. Few experimental studies on recurrent carious lesions in vivo have been reported, but bacteriological studies indicate that the etiology is similar to that of primary caries.

**Results.** Recurrent carious lesions are most often located on the gingival margins of Class II through V restorations. Recurrent caries is rarely diagnosed on Class I restorations. The diagnosis is difficult, and it is important to differentiate recurrent carious lesions from stained margins on resin-based composite restorations. Overhangs, even minute in size, are predisposed to plaque accumulation and the development of recurrent caries. The development of recurrent lesions is unrelated to microleakage.

**Clinical Implications.** As recurrent carious lesions are localized and limited, alternative treatments to restoration replacement are suggested. Polishing may be sufficient. If not, exploratory preparations into the restorative material adjacent to the localized defect can reveal the extent of the lesion. Such explorations invariably show that the lesion does not progress along the tooth-restoration interface. The defect, therefore, may be repaired in lieu of being completely replaced. Repair and refurbishing of restorations save tooth structure. These simple procedures also increase the life span of the restoration.

**Key Words.** Recurrent caries; case reports; microleakage; practice-based research.



surface. Caries left behind, intentionally or unintentionally, during restorative treatment is referred to as “remaining caries,” which may be at the cavity margin or, more commonly, in the dentin under a restoration.

### **FREQUENCY OF DIAGNOSED RECURRENT CARIES**

Ever since the G.V. Black period, the clinical diagnosis of recurrent caries has been shown in studies from many countries, including the United States, to be the most common reason by far for replacement of all types of restorations in permanent and primary teeth.<sup>2-23</sup> The percentage of restorations in adults that were replaced because of the clinical diagnosis of recurrent caries was consistently about 50 percent, with a range of 45 to 55 percent. The percentage was somewhat more for amalgam than for resin-based composite restorations, and it was somewhat less for restorations in primary teeth because of the relatively high percentage of bulk fractures of restorations in these teeth and their short life spans. Recurrent caries and discoloration of resin-based composite restorations combined represent a higher percentage of replacements than do recurrent caries for amalgam restorations alone. The restorations replaced as a result of the diagnosis of recurrent caries is much higher in general dental practice than in controlled clinical trials in which recurrent caries represents 2 to 3 percent of the failures.<sup>24</sup>

The ratio of restoration replacement to primary restorations in general dental practice has been reported to be as high as 80:20 for resin-based composite restorations and 70:30 for amalgam restorations,<sup>7</sup> and even higher ratios have been reported.<sup>25</sup> More recent studies indicate that this ratio is about 50:50 for restorations in permanent teeth.<sup>14-18,20</sup> This ratio apparently moved toward the 50:50 level for replaced primary restorations in Scandinavia in the 1980s.<sup>9,10,26,27</sup> Many factors affect this ratio, including the age of the population studied and the replacement ratio being higher in the permanent teeth of adolescents than in adults and being lower in the primary dentition.<sup>9,10,25</sup> The status of patient's oral health and dental care, including participation in caries prevention programs, also plays a role.

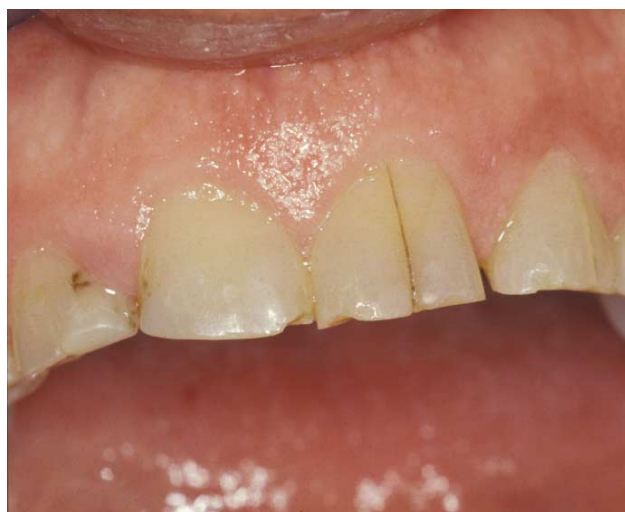On the basis of the information presented, it may be concluded that the clinical diagnosis of recurrent caries constitutes a major part of the dental treatment provided to patients in a general dental practice. This diagnosis may result in billions of dollars in restorative treatment worldwide. Therefore, it is important to analyze the available knowledge on the nature of recurrent caries and to explore possible preventive and alternative treatments to replace restorations that have received this diagnosis.

### **LOCATION OF CLINICALLY DIAGNOSED RECURRENT CARIES**

Studies have been conducted in which general practitioners were asked to indicate where recurrent carious lesions were located on diagrams of teeth, with outlines of the extent of the restorations examined.<sup>28-30</sup> These studies have shown that recurrent caries was seen predominantly on the gingival margins of all types of Class II through Class V restorations, while it was rarely associated with Class I restorations or on the occlusal part of Class II restorations. Recurrent caries was seen more often on the occlusal part of resin-based composite restorations than on the amalgam restorations. These findings will not surprise experienced clinicians.

Several factors may predispose a person to recurrent caries that is seen primarily on the gingival surface. This area is prone to contamination during the restoration by gingival fluid and saliva leaking between the matrix and the cavosurface margin, especially if a rubber dam is not used. As soon as the first portion of the restorative material is inserted, it obscures the gingival floor, making visual inspection difficult or impossible. Deficiencies in the adaptation of the restorative materials may cause voids that may lead to recurrent caries.<sup>31,32</sup> Polymerization shrinkage of resin-based materials also tends to cause crevices at the gingival margins when the curing light is used from the occlusal aspect. Bonding to dentin and cementum also is less effective at the gingival cavosurface margin than is bonding to enamel. Thus, polymerization shrinkage will tend to pull the material away from the gingival part of the cavity preparation, which often is located in dentin and cementum. Furthermore, the gingival aspect

.....  
**Clinical diagnosis of recurrent caries constitutes a major part of the dental treatment provided to patients in a general dental practice.**  
 .....



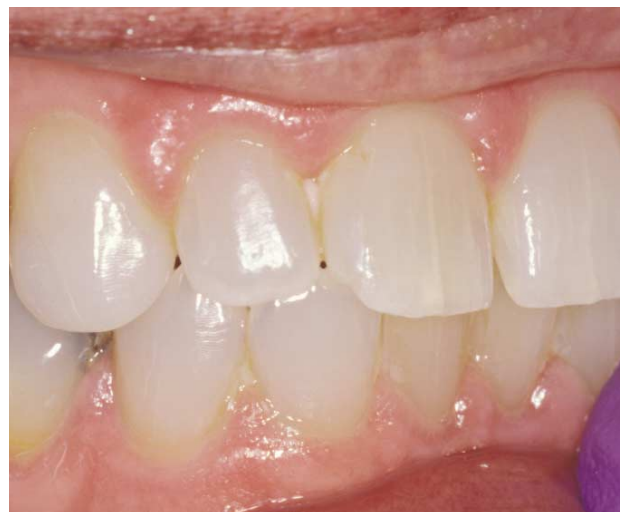**Figure 1. Vertical crack in the enamel of the right maxillary central incisor of an adult. The crack is stained but not carious.**

of any restoration is more difficult for patients to keep plaque-free than any other part, especially if it is located interproximally. Finally, the gingival margins of Class II through Class IV restorations are difficult to examine clinically because it is not possible to view them directly and the explorer tends to stick regardless of whether the cavosurface margin is carious. Thus, a number of factors predispose a patient to the diagnosis of recurrent caries at the gingival margin of restorations.

#### **BACTERIOLOGY OF RECURRENT CARIES**

Little attention has been paid to the microbiology of recurrent caries. Kidd and colleagues<sup>33</sup> performed cultures on samples of dentin taken from the dentinoenamel junction at intervals during cavity preparation using a rubber dam. They found no significant differences in the microflora in samples from cavity walls involving primary and recurrent caries.

The amount of plaque and its cariogenicity at restoration margins depends on the restorative material.<sup>34-38</sup> These findings indicate that resin-based materials accumulate more plaque, and this plaque is more cariogenic than that seen on amalgam, silicate cement and glass ionomer materials. Practice-based studies have shown that there is no difference in the relative frequency of replacement of such restorations owing to a diagnosis of recurrent caries with the exception of silicate cement restorations, which were known to prevent recurrent caries but dissolved *in situ*.<sup>17,18</sup> These findings raise legitimate questions regarding the diagnosis. Is it really caries that is diagnosed?

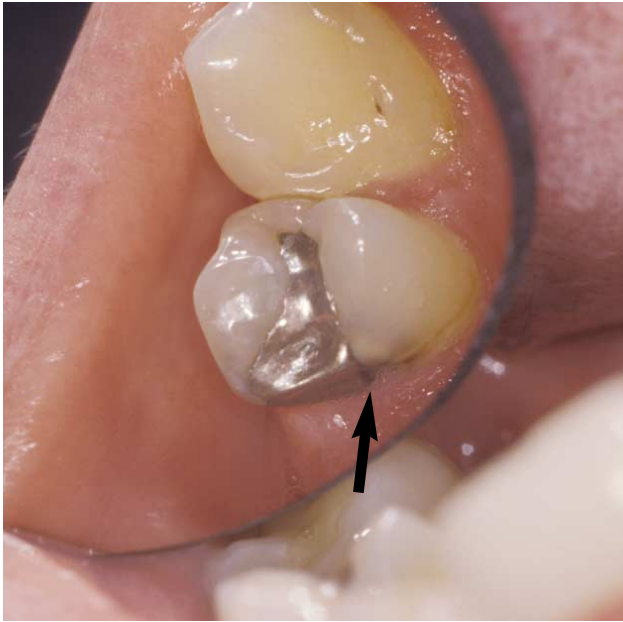


**Figure 2. Vertical cracks in the left maxillary central incisor of a 22-year-old person. The cracks are unstained and not carious.**

Microleakage also has been associated with the development of recurrent caries,<sup>39,40</sup> but this view has been challenged. One study indicated that crevices at the tooth-restoration interface of less than 35 to 50 micrometers do not predispose a patient to the development of recurrent caries, while larger crevices do.<sup>41</sup> However, the bulk of available evidence indicates that there is no relationship between the development of recurrent caries and the size of the crevice at the tooth-restoration interface,<sup>42-47</sup> except in cases of macroleakage in which the crevice exceeded 250  $\mu\text{m}$ <sup>42</sup> or 400  $\mu\text{m}$ .<sup>48</sup> Thus, recurrent caries does not develop as a result of microleakage along the tooth-restoration interface, but it is a surface lesion similar to primary carious lesions on smooth surfaces.<sup>42,49</sup> The presence of overhangs—even minute overhangs that are difficult to detect clinically—predispose a patient to the development of recurrent caries, indicating that plaque accumulation is an important predisposing factor in the development of recurrent caries.<sup>42</sup>

The best clinical evidence that microleakage does not lead to the development of caries may be found by observing cracks in teeth (Figures 1 and 2). Carious lesions never seem to develop in these cracks or the adjacent areas, but they clearly pick up stains over time, not unlike those sometimes seen at the margin of tooth-colored restorations. The stained component is considered to be the proteinaceous material in the crack or crevice, and it is similar in composition to that of the pellicle that normally covers all teeth and restorations.

Bacteria have been found at the restoration-



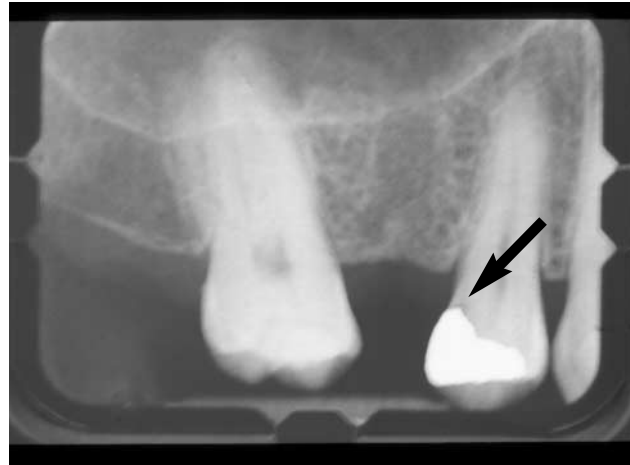
**Figure 3. Photograph showing a recurrent carious lesion (arrow) in a maxillary premolar at the gingivolingual aspect of a Class II amalgam restoration.**

cavity interface and have been shown to cause pulpal reactions in short-term experiments in newly erupted teeth.<sup>50,51</sup> This finding, however, should not be confused with the development of recurrent caries. In this context, one also should note that most oral bacteria are nonpathogenic, and the bacteria demonstrated by histobacteriological techniques may not be cariogenic.

### DIAGNOSIS OF RECURRENT CARIES

Recurrent caries at proximal or gingival locations in restorations can be diagnosed by radiography provided the X-rays are at an optimal angle in relation to the lesion. Because restorative materials are radiopaque, they may hide the lesion completely or partially (Figures 3 and 4). The burnout that frequently occurs at the cervical margin also may make interpretation difficult. In general, the diagnosis of recurrent caries lacks consistency,<sup>52-56</sup> and the diagnostic variations among clinicians are astounding.<sup>44</sup> These differences reflect the subjective disparities that characterize teaching in this area.<sup>56</sup> Similar ill-defined and subjective criteria were described by almost 300 general practitioners in the diagnosis of recurrent caries (I.A.M., unpublished data, 2004). Thus, clinical practice reflects the state of education, and this flawed process points to the need for a change.

Stains at the margins of tooth-colored restora-



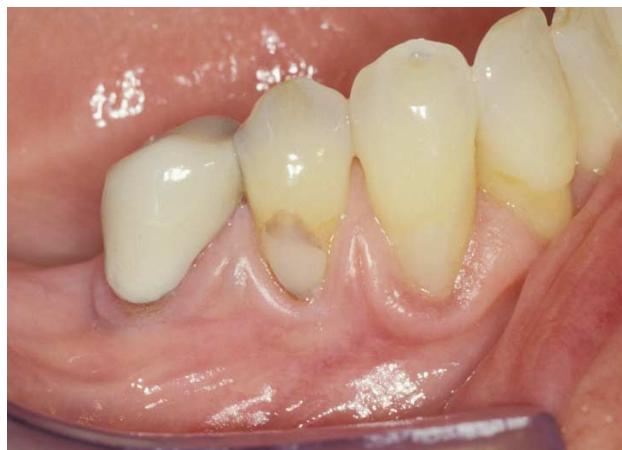**Figure 4. Radiograph of the premolar shown in Figure 3 with recurrent carious lesion (arrow) partially hidden by the radiopaque amalgam restoration.**

tions are difficult to differentiate from recurrent caries.<sup>57,58</sup> As in cracks (Figure 1), fissures and pits, stain is not a reliable predictor of the presence of recurrent caries; in fact, only frankly cavitated carious lesions at restoration margins constitute a reliable diagnosis of recurrent caries.<sup>58</sup>

Based on the available evidence and confirmed clinical experience, ditched and stained margins, as well as true recurrent caries, are localized defects that may be repaired or refurbished. In this context, it is noteworthy that commonly observed ditched margins on restorations are characteristic features of the occlusal surface of amalgam restorations and resin-based composite restorations.<sup>18</sup> However, they rarely develop carious lesions, because recurrent carious lesions seldom are diagnosed on the occlusal surface. In fact, a study of ditched and nonditched margins of amalgam restorations has shown that there is no difference in the presence of carious lesions in the two situations.<sup>47</sup> It is important in this situation to keep in mind that an explorer will stick in any crevice, regardless of whether it is carious.

### THE TREATMENT OF RECURRENT CARIES

The clinical diagnosis of recurrent caries invariably has resulted in the replacement of the restoration affected. But this clinical approach to the problem has been challenged.<sup>59</sup> If clinically diagnosed recurrent caries often is a marginal defect rather than a carious lesion, it is unlikely that fluoride or other materials releasing known caries-preventing agents will reduce the frequency with which recurrent caries is diagnosed. In fact, practice-based cross-sectional studies of

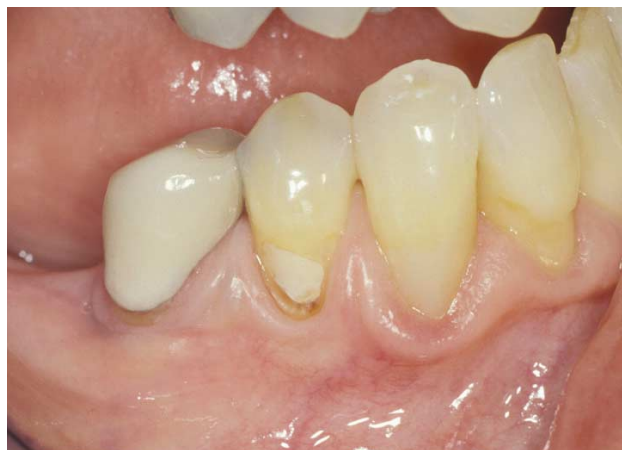

**Figure 5.** Discolored area at the occlusal aspect of the Class V restoration in the mandibular first premolar. This defect and the slight gingival defect were diagnosed as recurrent carious lesions.

reasons for restoration replacement show that glass ionomer restorative materials most often are replaced under the diagnosis of recurrent caries.<sup>17,18</sup> This finding by itself, coupled with the relatively short life span of glass ionomer cement restorations, indicates that the caries-preventive properties of restorative materials will not affect the restoration replacement rate, except in extreme situations such as when the patient has xerostomia.<sup>60</sup> Again the clinical diagnosis must be questioned. In vitro studies have shown that glass ionomer cements reduce the incidence and severity of recurrent caries,<sup>61</sup> but this finding has not been verified clinically and care should be exercised when applying the results of in vitro studies to the clinical situation.<sup>62</sup>

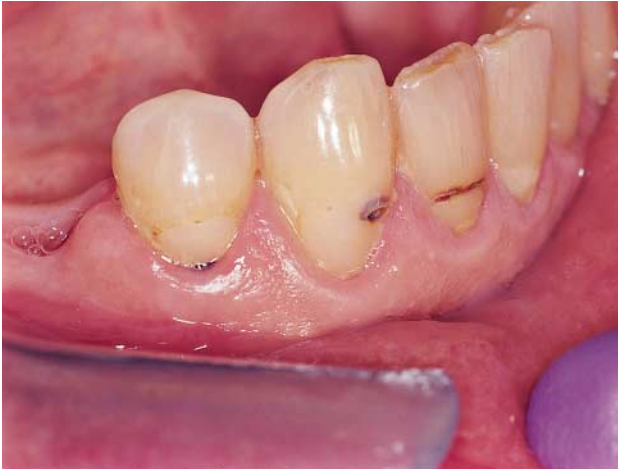Based on the evidence available, which shows that clinically diagnosed recurrent caries is a localized surface defect adjacent to restorations, a reassessment of the treatment approach is recommended. It must be recognized that discoloration is but one sign of carious lesions; another is softening of the tissues, including disintegration and eventually cavity formation. As the lesion reaches dentin, the wetness of the lesion also is a relevant clinical criterion.<sup>33</sup> These three characteristics of carious lesions—softening of the tissues, discoloration and wetness of the lesions—are essential for differentiating active from arrested carious lesions. This differentiation is made routinely in primary caries, and it has treatment implications. However, such differentiations are, surprisingly, not made relative to recurrent caries.

Practitioners should consider repairing and refurbishing any localized defects at restoration



**Figure 6.** A brief grinding of the stained part of the restoration shown in Figure 5 with a fine finishing bur removed the stain under the resin flash. The small, discolored gingival defect was hard and was left untreated for monitoring of future progression.

margins, including clinically diagnosed recurrent caries, rather than performing a total replacement. I have successfully employed this approach in the last three to four years to the extent that they have become routine procedures. Discolored areas adjacent to restorations may be misdiagnosed as recurrent carious lesions (Figure 5). Occasionally, the localized discolorations are caused by stain under resin flash beyond the extent of the cavosurface margin. Grinding with a fine finishing bur to remove the stain under the resin flash can alleviate the problem (Figure 6). Other times, the stain cannot be removed by grinding, and a small exploratory preparation should be made. Figures 7 through 9 illustrate the clinical procedures I adopted in a case in which the Class V restorations in the lateral incisor, the canine and premolar had stained discrepancies on the gingival margin, and the lateral incisor also had stained discrepancies on the incisal part of the restoration (Figure 7). All of the restorations were diagnosed as having recurrent caries and were scheduled for replacement. Under my supervision, a dental student subjected the stained margin on the lateral incisor to grinding but could not remove the stain. The student then carefully approached all the stained margins from the restoration side. This exploratory preparation provided information about the extent of the lesion and removed the stain. The student confirmed the localized nature of the defects (Figure 8) and prepared them for repair by removing small parts of the resin-based composite material adjacent to the stained margins. As the defects

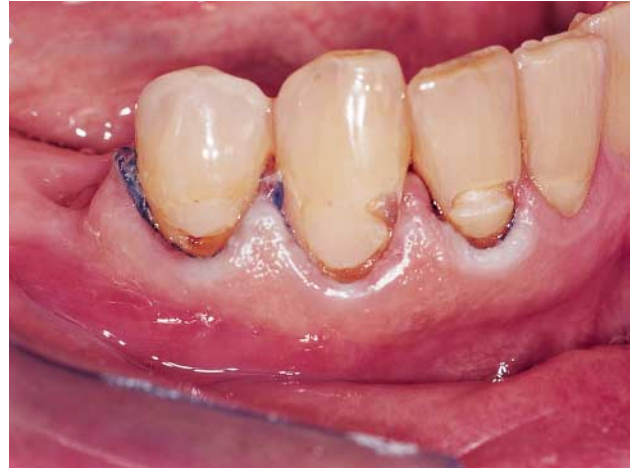

**Figure 7.** The Class V restorations in the lateral incisor, the canine and the premolar had stained discrepancies on the gingival aspect, and the lateral incisor also had stained discrepancies on the incisal aspect of the restoration. All of the restorations were diagnosed as having recurrent carious lesions.

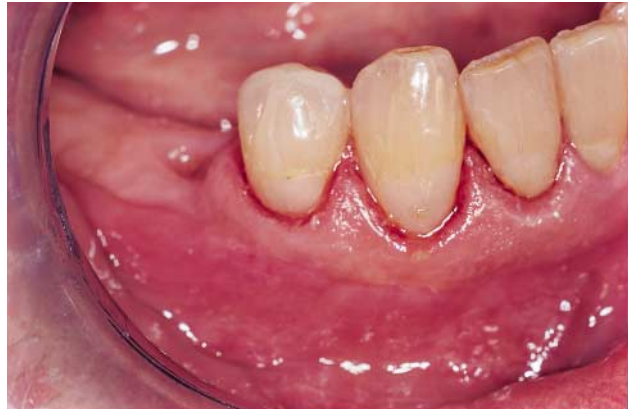did not extend deep into the tooth-restoration interface, the cavities were considered suitable for repair using a conventional restorative technique. The student then repaired the defects (Figure 9). The student treated ditched margins on amalgam restorations similarly by opening up the ditch from the amalgam side and then restoring the exploratory preparation whenever it was confirmed that the lesion was limited and localized.<sup>63</sup>

Dental teaching programs related to localized defects on restorations, including recurrent caries, indicate that repair, rather than replacement, of the restoration is adopted frequently as an alternative to total replacement.<sup>63-67</sup> In North America, about 71 percent of dental schools teach how to repair resin-based composite restorations. The majority of dental schools consider repair to be a definitive measure and reported that an acceptable life span of repaired restorations was four years.<sup>67</sup> Furthermore, the minimal intervention approach to restorative dentistry calls for repair rather than total replacement of restorations with localized defects.<sup>68</sup>

Reviews of literature and additional in vitro studies on the bonding between old and new materials used for repair of resin-based composite restorations<sup>69</sup> and amalgam restorations<sup>70</sup> indicate that the bond strength between new and old materials is less than that of intact specimens, but it generally is considered clinically acceptable. Diligent use of clinical techniques is required. Preparation of undercuts in the old material does not necessarily improve the repair



**Figure 8.** The three Class V restorations with localized defects shown in Figure 7 were prepared for repair by removing a small part of the composite material adjacent to the stained margins.



**Figure 9.** The localized defects at the cavosurface margins of the three Class V restorations immediately after the defects had been repaired and the gingival cord has been removed.

bond strengths, because of the difficulties in adequately filling the undercuts. My clinical experience with repair of amalgam restorations confirms the results of Smales and Hawthorne.<sup>71</sup> Resin-based composite restorations also may be repaired and refurbished successfully, and longevity studies of such restorations are in progress.

## CONCLUSIONS

Uncertainty exists with regard to the clinical diagnosis of recurrent caries. A review of the literature demonstrates marked deviations in this diagnosis among clinicians. Surveys have shown great variations in or lack of defined criteria to characterize these lesions. Teeth with stained margins of tooth-colored restorations and ditched margins in which the explorer tends to stick often

are misdiagnosed as having recurrent caries. It appears that only frankly cavitated carious lesions adjacent to restorations indicate true recurrent carious lesions. If located interproximally, these lesions may be diagnosed radiographically under favorable conditions. Recurrent carious lesions and ditched and discolored cavosurface margins of restorations are all localized defects that may be repaired or refurbished. If even after using recognized clinical criteria to diagnose recurrent caries there still is any uncertainty, exploratory preparations into the restorative material adjacent to the defects will determine their extent and will allow a firm diagnosis to be made. This will determine the need for repair or replacement of the restoration. ■

Dr. Mjör is a professor of Operative Dentistry and the Academy 100 Eminent Scholar, University of Florida College of Dentistry, P. O. Box 100415, Gainesville, Fla. 32610, e-mail "imjor@dental.ufl.edu". Address reprint requests to Dr. Mjör.

This article was supported by grant DE13412 from the National Institutes of Health, National Institute of Dental and Craniofacial Research.

The illustrations in this article are all from the Operative Dentistry Clinic 2A, College of Dentistry, University of Florida. The treatments illustrated were performed by dental students and supervised by Dr. Mjör. Eduardo B. Mondragon photographed the clinical cases.

- Black GV. A work on operative dentistry. Chicago: Medico-Dental Publishing; 1908. The technical procedures in filling teeth; Vol. 2.
- Healy HJ, Philips RW. A clinical study of amalgam failures. *J Dent Res* 1949;28:439-46.
- Moss RP Jr. Amalgam failures. *US Armed Forces Med J* 1953;4:735-6.
- Fusayama T, Hosoda H, Iwamoto T. An improved self-curing acrylic restoration and comparison with silicate cement restorations. *J Prosthet Dent* 1964;14:537-53.
- Lavelle CLB. A cross-sectional longitudinal survey into the durability of amalgam restorations. *J Dent* 1976;4:139-43.
- Dahl JE, Eriksen HM. Reasons for replacement of amalgam restorations. *Scand J Dent Res* 1978;86:404-7.
- Mjör IA. Placement and replacement of restorations. *Oper Dent* 1981;6:49-54.
- Klausner LH, Green TG, Charbeneau GT. Placement and replacement of amalgam restorations: a challenge for the profession. *Oper Dent* 1987;12:102-12.
- Qvist J, Qvist V, Mjör IA. Placement and longevity of amalgam restorations in Denmark. *Acta Odontol Scand* 1990;48:297-303.
- Qvist V, Qvist J, Mjör IA. Placement and longevity of tooth-colored restorations in Denmark. *Acta Odontol Scand* 1990;48:305-11.
- Mjör IA, Toffenetti F. Placement and replacement of amalgam restorations in Italy. *Oper Dent* 1992;17(2):70-3.
- Mjör IA, Toffenetti F. Placement and replacement of resin-based composite restorations in Italy. *Oper Dent* 1992;17(3):82-5.
- Mjör IA, Um CM. Survey of amalgam and composite restorations in Korea. *Int Dent J* 1993;43:311-6.
- Pink FE, Minden NJ, Simmonds S. Decisions of practitioners regarding placement of amalgam and composite restorations in general practice settings. *Oper Dent* 1994;19:127-32.
- Friedl KH, Hiller KA, Schmalz G. Placement and replacement of amalgam restorations in Germany. *Oper Dent* 1994;19:228-32.
- Friedl KH, Hiller KA, Schmalz G. Placement and replacement of composite restorations in Germany. *Oper Dent* 1995;20:34-8.
- Mjör IA. The reasons for replacement and the age of failed restorations in general dental practice. *Acta Odontol Scand* 1997;55(1):58-63.
- Mjör IA, Moorhead JE, Dahl JE. Reasons for replacement of restorations in permanent teeth in general dental practice. *Int Dent J* 2000;50:360-6.
- Deligeorgi V, Wilson NH, Fouzas D, Kouklaki E, Burke FJ, Mjör IA. Reasons for placement and replacement of restorations in student clinics in Manchester and Athens. *Euro J Dent Educ* 2000;4(4):153-9.
- Mjör IA, Shen C, Eliasson ST, Richter S. Placement and replacement of restorations in general dental practice in Iceland. *Oper Dent* 2002;27(2):117-23.
- Qvist V, Laurberg L, Poulsen A, Teglers PT. Eight-year study on conventional glass ionomer and amalgam restorations in primary teeth. *Acta Odontol Scand* 2004;62(1):37-45.
- Qvist V, Manscher E, Teglers PT. Resin-modified and conventional glass ionomer restorations in primary teeth: 8-year results. *J Dent* 2004 May;32(4):285-94.
- Qvist V, Laurberg L, Poulsen A, Teglers PT. Class II restorations in primary teeth: 7-year study on three resin-modified glass ionomer cements and a compomer. *Euro J Oral Sci* 2004;112(2):188-96.
- Letzel H, van't Hof MA, Vrijhoef MA, Marshall GW, Marshall SJ. Failure, survival, and reasons for replacement of amalgam restorations. In: Anusavice KJ, ed. *Quality evaluation of dental restorations*. Chicago: Quintessence; 1989:83-92.
- Mjör IA. Amalgam and composite restorations: longevity and reasons for replacement. In: Anusavice KJ, ed. *Quality evaluation of dental restorations*. Chicago: Quintessence; 1989:61-8.
- Qvist V, Thylstrup A, Mjör IA. Restorative treatment pattern and longevity of amalgam restorations in Denmark. *Acta Odontol Scand* 1986;44:343-9.
- Qvist V, Thylstrup A, Mjör IA. Restorative treatment pattern and longevity of resin restorations in Denmark. *Acta Odontol Scand* 1986;44:351-6.
- Mjör IA. The frequency of secondary caries at various anatomical locations. *Oper Dent* 1985;10(3):88-92.
- Mjör IA, Qvist V. Marginal failures of amalgam and composite restorations. *J Dent* 1997;25(1):25-30.
- Mjör IA. The location of clinically diagnosed secondary caries. *Quintessence Int* 1998;29:313-7.
- Mjör IA, Smith DC. Detailed evaluation of six Class II amalgam restorations. *Oper Dent* 1985;10(1):17-21.
- Qvist V. Resin restorations: leakage, bacteria, pulp. *Endod Dent Traumatol* 1993;9(4):127-52.
- Kidd EA, Joyston-Bechal S, Beighton D. Microbiological validation of assessments of caries activity during cavity preparation. *Caries Res* 1993;27:402-8.
- Sønju T, Glantz PO. Chemical composition of salivary integuments formed in vivo on solids with some established surface characteristics. *Arch Oral Biol* 1975;20:687-91.
- Ørstavik D, Ørstavik J. In vitro attachment of *Streptococcus sanguis* to dental crown and bridge cements. *J Oral Rehabil* 1976;3(2):139-44.
- Skjørland KK. Auger analysis of integuments formed on different dental filling materials in vivo. *Acta Odontol Scand* 1982;40(3):129-34.
- Svanberg M, Mjör IA, Ørstavik D. Mutans streptococci in plaque from margins of amalgam, composite, and glass ionomer restorations. *J Dent Res* 1990;69:861-4.
- Moura JS, Lima EM, Paes Leme AF, Del Bel Cury AA, Tabchoury CP, Cury JA. Effect of luting cement on dental biofilm composition and secondary caries around metallic restorations in situ. *Oper Dent* 2004;29:509-14.
- Kidd EA. Microleakage: a review. *J Dent* 1976;4(5):199-206.
- Kidd EA. Caries diagnosis within restored teeth. In: Anusavice KJ, ed. *Quality evaluation of dental restorations*. Chicago: Quintessence; 1989:111-21.
- Jørgensen KD, Wakumoto S. Occlusal amalgam fillings: marginal defects and secondary caries. *Odontol Tidskr* 1968;76(1):43-54.
- Özer L. The relationship between gap size, microbial accumulation and the structural features of natural caries in extracted teeth with Class II amalgam restorations [master's thesis]. Copenhagen, Denmark: University of Copenhagen; 1997.
- Goldberg J, Tanzer J, Munster E, Amara J, Thal F, Birkhed D. Cross-sectional clinical evaluation of recurrent enamel caries, restoration of marginal integrity, and oral hygiene status. *JADA* 1981;102:635-41.
- Merrett MC, Elderton RJ. An in vitro study of restorative dental treatment decisions and dental caries. *Br Dent J* 1984;157(4):128-33.
- Söderholm KJ, Antonson DE, Fishlschweiger W. Correlation between marginal discrepancies at the amalgam/tooth interface and recurrent caries. In: Anusavice KJ, ed. *Quality evaluation of dental restorations*. Chicago: Quintessence; 1989:85-108.
- Kidd EA, O'Hara JW. Caries status of occlusal amalgam restora-

- tions with marginal defects. *J Dent Res* 1990;69:1275-7.
47. Pimenta LA, Navarro MF, Consolaro A. Secondary caries around amalgam restorations. *J Prosthet Dent* 1995;74:219-22.
48. Kidd EA, Joyston-Bechal S, Beighton D. Marginal ditching and staining as a predictor of secondary caries around amalgam restorations: a clinical and microbiological study. *J Dent Res* 1995;74:1206-11.
49. Mjör IA, Toffenetti F. Secondary caries: a literature review with case reports. *Quintessence Int* 2000;31(3):165-79.
50. Brännström M. Caries. In: *Dentine and pulp in restorative dentistry*. London: Wolfe Medical; 1982:chap 2.
51. Cox CF. Microleakage related to restorative procedures. *Proc Finn Dent Soc* 1992;88(supplement 1):83-93.
52. Espelid I, Tveit AB. Diagnosis of secondary caries and crevices adjacent to amalgam. *Int Dent J* 1991;41:359-64.
53. Tveit AB, Espelid I. Class II amalgams: interobserver variations in replacement decisions and diagnosis of caries and crevices. *Int Dent J* 1992;42(1):12-8.
54. Bader JD, Shugars DA. Understanding dentists' restorative treatment decisions. *J Public Health Dent* 1992;52(2):102-10.
55. Kidd EA, Joyston-Bechal S, Beighton D. Diagnosis of secondary caries: a laboratory study. *Br Dent J* 1994;176(4):135-9.
56. Clark TD, Mjör IA. Current teaching of cariology in North American dental schools. *Oper Dent* 2001;26:412-8.
57. Tyas MJ. Cariostatic effect of glass ionomer cement: a five-year clinical study. *Aust Dent J* 1991;36:236-9.
58. Kidd EA, Beighton D. Prediction of secondary caries around tooth-colored restorations: a clinical and microbiological study. *J Dent Res* 1996;75:1942-6.
59. Mjör IA. Repair versus replacement of failed restorations. *Int Dent J* 1993;43:466-72.
60. McComb D, Erickson RL, Maxymiw WG, Wood RE. A clinical comparison of glass ionomer, resin-modified glass ionomer and resin composite restorations in the treatment of cervical caries in xerostomic head and neck radiation patients. *Oper Dent* 2002;27:430-7.
61. Swift EJ Jr. Effect of glass ionomers on recurrent caries. *Oper Dent* 1989;14:40-3.
62. Sá LT, Gonzalez-Cabezas C, Cochran MA, Fontana M, Matis BA, Moore BK. Fluoride releasing materials: their anti-cariogenic properties tested in in vitro caries models. *Oper Dent* 2004;29:524-31.
63. Mjör IA, Gordan VV. Failure, repair, refurbishing, and longevity of restorations. *Oper Dent* 2002;27:528-34.
64. Blum IR, Schriever A, Heidemann D, Mjör IA, Wilson NH. Repair versus replacement of defective direct composite restorations in teaching programmes in United Kingdom and Irish dental schools. *Eur J Prosthodont Rest Dent* 2002;10(4):151-5.
65. Blum I, Schriever A, Heidemann D, Mjör IA, Wilson NH. The repair of direct composite restorations: an international study of the teaching of operative techniques and materials. *Eur J Dent Educ* 2003;7(1):41-8.
66. Blum I, Mjör IA, Schriever A, Heidemann D, Wilson NH. Defective direct composite restorations: replace or repair?—a survey of teaching in Scandinavian dental schools. *Swed Dent J* 2003;27:99-104.
67. Gordon VV, Mjör IA, Blum IR, Wilson N. Teaching students the repair of resin-based composite restorations: a survey of North American dental schools. *JADA* 2003;134:317-23.
68. Ericson D, Kidd E, McComb D, Mjör I, Noack MJ. Minimally invasive dentistry: concepts and techniques in cariology. *Oral Health Prev Dent* 2003;1(1):59-72.
69. Shen C, Mondragon E, Gordan VV, Mjör IA. The effect of mechanical undercuts on the strength of composite repair. *JADA* 2004;135:1406-12.
70. Shen C, Speigel J, Mjör IA. Repair strength of dental amalgams. *Oper Dent*. In press.
71. Smales RJ, Hawthorne WS. Long-term survival of repaired amalgams, recemented crowns and gold castings. *Oper Dent* 2004;29:249-53.